

Review Article

The SAPIEN-XT and SAPIEN-3 Valves: How to Implant and Obtain the Best Outcomes

ANTONIOS HALAPAS¹, MICHAEL CHRISSEHERIS¹, NIKOLAOS BOUBOULIS², SPYRIDON SKARDOUTSOS², IOULIA NIKOLAOU², STRATIS PATTAKOS, KONSTANTINOS SPARGIAS¹

Departments of ¹Transcatheter Heart Valves and ²Cardiothoracic Surgery, Hygeia Hospital, Athens, Greece

Key words:
Aortic stenosis,
transcatheter
aortic valve
implantation,
Edwards SAPIEN.

Transcatheter aortic valve implantation (TAVI) has become the treatment of choice for symptomatic severe aortic stenosis (AS) in “inoperable” patients and is non-inferior to surgical aortic valve replacement (sAVR) in “high-risk” operable patients.¹⁻⁴ Since the first-in-human (FIM) TAVI in 2002 with the Cribier-Edwards valve, the procedure continues to be refined, with technological improvements making the process simpler and clinical results better. The fourth-generation SAPIEN 3 valve of Edwards Lifesciences is currently in use, after the Cribier-Edwards, SAPIEN and SAPIEN XT valves.⁵⁻¹⁰ Current efforts focus on minimizing access site complications, stroke risk, paravalvular regurgitation (PVR), and atrioventricular (AV) block while facilitating accurate positioning.

The SAPIEN valve family has been used in the treatment of more than 70,000 patients globally, most of them treated with the SAPIEN XT. Recently (16 June 2014), the Edwards SAPIEN XT transcatheter aortic heart valve (THV) received approval from the US Food and Drug Administration (FDA) for the treatment of high-risk and inoperable patients suffering from severe AS. The new generation valve SAPIEN 3 (S3) is a further development of the SAPIEN XT and incorporates features to reduce vascular complications and PVR. Furthermore, the

new generation delivery system allows easier and more precise aortic valve positioning and implantation. The S3 valve was approved in Europe in January 2014; however, it is an investigational device that is not yet commercially available in the US and is currently being evaluated in the PARTNER-2 Trial.

Edwards SAPIEN-XT and SAPIEN-3 valves

The SAPIEN XT is a tri-leaflet bovine pericardial tissue valve mounted on a cobalt-chromium alloy stent and is available in four sizes: 20 mm (for dimensions of aortic annulus 16-18 mm), 23 mm (for dimensions of aortic annulus 18-22 mm), 26 mm (for dimensions of aortic annulus 22-25 mm) and 29 mm (for dimensions of aortic annulus 24-28 mm) (Figure 1).

A substantial reduction of the delivery system NovaFlex⁺ profile, combined with a lower-profile expandable sheath (eSheath, Edwards Lifesciences), resulted in a reduction of the dimensions of the introducer sheath. This was achieved by using a thinner stainless steel alloy stent and by crimping the SAPIEN XT proximal to the balloon on the catheter shaft and aligning the valve onto the balloon inside the descending aorta.

The Edwards eSheath (self-expandable and re-collapsible sheath allowing a partial arterial dilatation of ~3 F) is avail-

Address:
Konstantinos Spargias

THV Department,
Hygeia Hospital
9 Red Cross St.
151 23, Athens, Greece
spargias@hygeia.gr

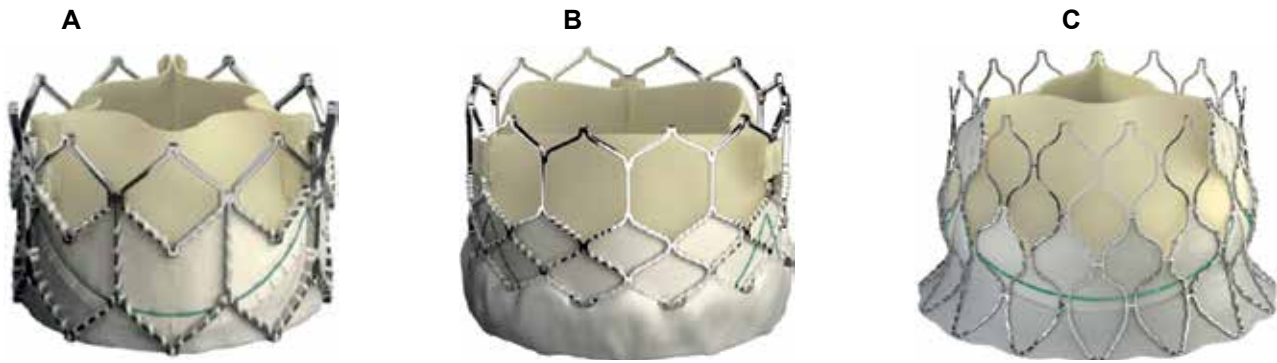


Figure 1. Edwards SAPIEN XT (A), SAPIEN 3 (B), and CENTERA (C).

able in unexpanded inner diameters of 16, 18, and 20 F (external diameter 6.6, 7.2, and 7.8 mm) for the 23, 26, and 29 mm SAPIEN XT valves, while the recommended minimum vessel diameter is 6.0, 6.5, and 7.0 mm respectively (Table 1). The valve can be implanted through multiple approaches: transfemoral (TF), transapical (TA) or transaortic (TAo), and a few subclavian access cases have been reported. In addition, it is a device that can be used for implantation in degenerated aortic, mitral and tricuspid bioprotheses, in mitral valve rings, and for implantation in the pneumatic valve position within a supporting stent.¹¹⁻¹³

As with the earlier devices, the inflow of the newer generation S3 valve is covered by an internal polyethylene terephthalate (PET) skirt. However, the S3 incorporates an additional outer PET cuff that enhances sealing and minimizes PVR (Figure 1).^{9,10} Furthermore, the different frame geometry, with larger cells and wide strut angles, contributes to an ultra-low delivery profile and high radial strength. The delivery system of the S3 (Commander) is a further development of the NovaFlex⁺ SAPIEN XT delivery catheter and is characterized by: a) increased flexion

capabilities at two different levels (transverse aorta and final segment) for crossing the aortic arch and engaging the native valve in a more coaxial manner; b) more precise positioning of the valve by rotating a knob, with no need to push or pull the catheter; and finally c) a lower profile compared with the SAPIEN XT NovaFlex⁺ delivery system.

At present, the S3 is available in three sizes, 23, 26, and 29 mm (in addition a 20 mm valve is anticipated) with respective e-Sheath internal diameters 14, 14, and 16 F (external diameter 5.9, 5.9, and 6.6 mm), and recommended minimum vessel diameters 5.5, 5.5, and 6.0 mm (Table 1). Therefore, many patients previously considered unsuitable for femoral access because of small vessel diameters may safely undergo TAVI with the S3.

Edwards CENTERA valve

The Edwards CENTERA is a tri-leaflet bovine pericardial tissue valve currently available in three sizes: 23, 26, and 29 mm. In contrast to the SAPIEN family valves it is a self-expandable, re-sheathable and re-positionable valve attached to a low profile nitinol

Table 1. The SAPIEN valves. Dimensions of the sheaths, peripheral arteries and aortic annuli.

	Inner diameter of e-Sheath (F)	Minimum access vessel diameter (mm)	Native aortic annulus area (mm ²)
SAPIEN XT			
23 mm	16	6.0	300-414
26 mm	18	6.5	380-530
29 mm	20	7.0	490-660
SAPIEN 3			
23 mm	14	5.5	338-430
26 mm	14	5.5	430-546
29 mm	16	6.0	540-680

frame. The low frame height is designed to minimize conduction disturbances (Figure 1). The new generation motorized delivery system of the CENTERA can be delivered by the TF or subclavian approaches and is characterized by: a) high flexibility enhancing trackability and optimal coaxial alignment; b) a handle for controlled release and accurate positioning; and c) a low-profile 14F e-Sheath by Edwards. After the promising FIM clinical experience with the CENTERA (2010), we anticipate CE mark approval and its clinical use in Europe after the results of an ongoing multicenter study (150 consecutive patients). Finally, the safety and effectiveness of CENTERA in patients with high surgical risk (STS score >8% and EuroSCORE >15%) will be established by an ongoing randomized, multicenter prospective study (NCT01808274).¹⁴

Clinical data

The first available randomized data on TAVI came from the PARTNER trials, in which the first generation SAPIEN valve was studied (profile 22-24 F). In the PARTNER-B trial, inoperable patients with severe symptomatic aortic stenosis were randomized to either TF TAVI or medical treatment (including valvuloplasty).¹ The superiority of TAVI was indisputably proved, since the primary endpoint of death at 1 year was reduced by 45%. The PARTNER-A randomized trial demonstrated non-inferiority of TAVI compared to sAVR in high-risk patients.¹⁰ In particular, the one-year mortality in the TF treated patients was 4.2% lower than in their surgically treated counterparts. The PARTNER trial established TAVI as the gold-standard treatment for inoperable patients and as an alternative option for patients at high surgical risk. Furthermore, the SOURCE XT (SAPIEN XT Aortic Bioprosthesis European Outcome) registry showed good clinical results with low mortality (30-day mortality was 4.3% for the TF group and 9.9% for the TA group).¹¹ The safety and effectiveness of the SAPIEN XT in patients with moderate surgical risk (STS score 4-8%) is being studied by the ongoing PARTNER-IIA trial.

Vascular complications are a major cause of morbidity and mortality post-TAVI.¹⁵ The major vascular complication rates (according to the Valve Academic Research Consortium definitions) of TF groups using the SAPIEN valve in studies and registries ranged from 4% to 22.9%.^{16,17} In the PARTNER-A and B trials, the major vascular com-

plication rates were 11% and 16.2% respectively.^{1,2} Data from the PARTNER trials and other studies revealed that major vascular complications were correlated with increased mortality.¹⁵ The strongest predictor for vascular complications was the ratio of the outer diameter of the sheath to the minimal lumen diameter of the access vessel;¹⁸ when this was higher than 1.05 vascular complications increased significantly.¹⁹ Recent studies showed a major decrease in major vascular complications (down to 4%) with the use of the newer-generation SAPIEN XT valve.^{8,20,21} It is expected that the lower profile S3 valve with the 14 F e-Sheath will further reduce such complications.^{9,10}

PVR after TAVI has been associated with increased mortality.^{3,22} In the PARTNER-A and B trials, the incidence of moderate or severe PVR at 30 days was 12.2% and 11.8%, respectively.¹⁻³ Many studies have shown a lower PVR incidence with the balloon-expandable Edwards valve than with the self-expandable CoreValve. Indeed, in the FRANCE-2 registry, moderate or severe PVR was reported in 13.9% of TAVI patients (the corresponding incidence with the CoreValve was 22.5%).²³ In a recent meta-analysis of 12,926 patients, the incidence of moderate or severe PVR was 9.1% in the SAPIEN valve group (95% confidence interval: 6.2-13.1%) and 16% in the CoreValve group (95% confidence interval: 13.4-19%).²⁴ In the ADVANCE study of the CoreValve the corresponding percentage was 16%.²⁵ The CHOICE trial revealed a greater rate of device success and a lower rate of moderate or severe PVR for the balloon-expandable SAPIEN XT valve compared to the self-expandable CoreValve (0.0% vs 7.2%, $p=0.009$, and 2.1% vs. 9.6% for total PVR, $p=0.04$).²⁶ Recent data regarding the S3 valve revealed no moderate or severe PVR. Indeed, PVR was absent or trivial in 73% of patients and mild in the remainder.²⁷ In addition, in a multicenter study of the S3 (n=150 patients) no severe PVR was reported and moderate PVR was reported in only 3.4%.¹⁰ Possible explanations for these low PVR rates are the outer polyethylene terephthalate (PET) sealing cuff, the more accurate positioning, and the improved sizing with adjunctive multi-detector row computed tomography (MDCT) screening. The results of these studies indicate that the S3 valve may allow the treatment of intermediate-risk patients with AS by minimizing the risk of PVR.

Heart block necessitating permanent pacemaker implantation (PPI) is a concern after TAVI.²⁸ In-

terestingly, PPI is also a complication of sAVR, with an incidence of up to 11.8% (mean 7.0%, median 7.2%).²⁹ In a comparison study, the incidence of PPI for TAVI was double that for SAVR (7.3% versus 3.4%, $p=0.014$).³⁰ The large observational UK TAVI (United Kingdom Transcatheter Aortic Valve Implantation) and FRANCE-2 (French Aortic National CoreValve and Edwards) registries reported new pacemaker rates of 24.4% and 24.2%, respectively, with the CoreValve versus 7.4% and 11.5% with the SAPIEN/XT valves.^{23,31} Data from a recent meta-analysis revealed a three- to fourfold higher incidence of new PPI with the CoreValve (20.8%) versus the SAPIEN valves (5.4%).²⁹

How to implant to obtain the best outcome

The optimum short- and long-term results of patients who undergo TAVI depend mainly upon proper patient selection by the Heart Team. According to the recent guidelines, TAVI should be performed only in highly specialized centers that have a functional multidisciplinary Heart Team, consisting of interventional cardiologists, echo-cardiologists, clinical cardiologists, cardiac surgeons, cardio-anesthesiologists, intensivists, vascular surgeons, and specialized nursing and technical staff (indication IC). Furthermore, ideally such procedures should be performed in latest-generation hybrid operating rooms, which combine the characteristics of a fully functional cardio-surgery room with the imaging modalities of a catheterization laboratory.

Correct measurement of the aortic valve annulus is essential for the correct sizing of the THV valves. Under-sizing THVs is a potential cause of PVR and device embolization. However, aggressive oversizing might contribute to annular rupture, coronary obstruction, atrioventricular block, periaortic hematoma, ventricular septal rupture, or anterior mitral leaflet injury. Traditional sizing criteria based

on single-plane two-dimensional measurements do not appreciate the consistently oval-shaped anatomy of the aortic annulus. Recently, 3-dimensional (3D) annular assessments by MDCT and annulus area-based sizing have been shown to predict PVR, contributing to appropriate valve sizing.³² Sizing guidelines were developed to ensure that THVs are moderately but not excessively oversized relative to the annular area as assessed by MDCT (Table 1). For the balloon-expanding valves, it has been shown that relatively modest 5-10% area oversizing would be adequate. Under certain anatomical conditions (such as a heavily calcified aortic annulus or risk of coronary obstruction) even smaller oversizing (0-5%) is accepted, while in other cases (such as low leaflet and annulus calcium load) oversizing up to 15% is accepted. In addition, area oversizing by more than 20% has been shown to increase the risk of annular injury.³³ Finally, the strategy of under-expansion, with post-dilation as necessary, might play a role in reducing the risk of annular injury and PVR in selected patients.³⁴

Conclusion

Mounting experience with the newer-generation balloon-expandable valves (SAPIEN XT and S3) in well selected patients shows that the procedure has become more user friendly and results in better clinical outcomes. The latest SAPIEN family valves exceed the self-expandable CoreValve in many aspects, such as a less frequent need for PPI, a lower incidence of residual PVR, and lower profiles of the introducer sheaths. Moreover, they can be used in other cardiac valve diseases where a proper supporting structure exists (Table 2). However, the “Achilles’ heel” of the SAPIEN balloon expandable valves is that they are not re-sheathable or re-positionable, while they have a potential risk of annular rupture. The SAPIEN-3 is the latest-generation representative of the

Table 2. Advantages and limitations of the SAPIEN XT and S3 valves.

Advantages	Limitations
Lower incidence of conduction abnormalities and thus permanent pacemaker implantation	Neither re-sheathable nor re-positionable
Lower incidence of paravalvular regurgitation	Oversizing increases the risk of aortic annulus rupture
High flexibility, enhancing trackability and optimal coaxial alignment	Need for rapid ventricular pacing
Delivered through low-profile expandable e-Sheath	

Edwards valve family. It has a very low profile and an improved delivery system for more accurate positioning, thus eliminating the disadvantage of possible residual PVR. Finally, the very promising self-expandable valve (CENTERA) of Edwards Lifesciences is expected.

Disclosure

Dr. K. Spargias is Proctor for the aortic bioprosthesis SAPIEN (Edwards Lifesciences) and CoreValve (Medtronic).

References

- Leon MB, Smith CR, Mack M, et al. Transcatheter aortic valve implantation for aortic stenosis in patients who cannot undergo surgery. *N Engl J Med*. 2010; 363: 1597-1607.
- Smith CR, Leon MB, Mack MJ, et al. Transcatheter versus surgical aortic-valve replacement in high-risk patients. *N Engl J Med*. 2011; 364: 2187-2198.
- Kodali SK, Williams MR, Smith CR, et al; PARTNER Trial Investigators. Two-year outcomes after transcatheter or surgical aortic-valve replacement. *N Engl J Med*. 2012;366:1686-1695
- Adams DH, Popma JJ, Reardon MJ, et al; U.S. CoreValve Clinical Investigators. Transcatheter aortic-valve replacement with a self-expanding prosthesis. *N Engl J Med*. 2014; 370: 1790-1798.
- Cribier A, Eltchaninoff H, Bash A, et al. Percutaneous transcatheter implantation of an aortic valve prosthesis for calcific aortic stenosis: first human case description. *Circulation*. 2002; 106: 3006-3008.
- Webb JG, Chandavimol M, Thompson CR, et al. Percutaneous aortic valve implantation retrograde from the femoral artery. *Circulation*. 2006; 113: 842-850.
- Thomas M, Schymik G, Walther T, et al. One-year outcomes of cohort 1 in the Edwards SAPIEN Aortic Bioprosthesis European Outcome (SOURCE) registry: the European registry of transcatheter aortic valve implantation using the Edwards SAPIEN valve. *Circulation*. 2011; 124: 425-433.
- Vahanian A. The SOURCE XT TAVI Registry: Thirty-day outcomes in a 2,700 patients. International clinical registry with a second generation balloon-expandable transcatheter heart valve using multiple access techniques. Presented at EuroPCR, May 15-18, 2012, Paris.
- Binder RK, Rodés-Cabau J, Wood DA, et al. Transcatheter aortic valve replacement with the SAPIEN 3: a new balloon-expandable transcatheter heart valve. *JACC Cardiovasc Interv*. 2013; 6: 293-300.
- Webb J. 30-day outcomes from the SAPIEN 3 trial. Presented at EuroPCR, May 20-23, 2014, Paris.
- Schäfer U, Bader R, Frerker C, et al. Balloon-expandable valves for degenerated mitral xenografts or failing surgical rings. *EuroIntervention*. 2014; 10: 260-268.
- Laule M, Stangl V, Sanad W, Lembcke A, Baumann G, Stangl K. Percutaneous transfemoral management of severe secondary tricuspid regurgitation with Edwards Sapien XT bioprosthesis: first-in-man experience. *J Am Coll Cardiol*. 2013; 61: 1929-1931.
- Haas NA, Moysich A, Neudorf U, et al. Percutaneous implantation of the Edwards SAPIEN™ pulmonic valve: initial results in the first 22 patients. *Clin Res Cardiol*. 2013; 102: 119-128.
- Ribeiro HB, Urena M, Kuck KH, Webb JG, Rodés-Cabau J. Edwards CENTERA valve. *EuroIntervention*. 2012; 8 Suppl Q: Q79-82.
- Généreux P, Webb JG, Svensson LG, et al. Vascular complications after transcatheter aortic valve replacement: insights from the PARTNER (Placement of AoRTic TraNscatheter Valve) trial. *J Am Coll Cardiol*. 2012; 60: 1043-1052.
- Thomas M, Schymik G, Walther T, et al. Thirty-day results of the SAPIEN aortic Bioprosthesis European Outcome (SOURCE) Registry: A European registry of transcatheter aortic valve implantation using the Edwards SAPIEN valve. *Circulation*. 2010; 122: 62-69.
- Généreux P, Head SJ, Van Mieghem NM, et al. Clinical outcomes after transcatheter aortic valve replacement using valve academic research consortium definitions: a weighted meta-analysis of 3,519 patients from 16 studies. *J Am Coll Cardiol*. 2012; 59: 2317-2326.
- Hayashida K, Lefèvre T, Chevalier B, et al. True percutaneous approach for transfemoral aortic valve implantation using the Prostar XL device: impact of learning curve on vascular complications. *JACC Cardiovasc Interv*. 2012; 5: 207-214.
- Hayashida K, Lefèvre T, Chevalier B, et al. Transfemoral aortic valve implantation new criteria to predict vascular complications. *JACC Cardiovasc Interv*. 2011; 4: 851-858.
- Mussardo M, Latib A, Chieffo A, et al. Periprocedural and short-term outcomes of transfemoral transcatheter aortic valve implantation with the Sapien XT as compared with the Edwards Sapien valve. *JACC Cardiovasc Interv*. 2011; 4: 743-750.
- Toggweiler S, Gurvitch R, Leipsic J, et al. Percutaneous aortic valve replacement: vascular outcomes with a fully percutaneous procedure. *J Am Coll Cardiol*. 2012; 59: 113-118.
- Abdel-Wahab M, Zahn R, Horack M, et al. Aortic regurgitation after transcatheter aortic valve implantation: incidence and early outcome. Results from the German transcatheter aortic valve interventions registry. *Heart*. 2011; 97: 899-906.
- Gilard M, Eltchaninoff H, Iung B, et al. Registry of transcatheter aortic-valve implantation in high-risk patients. *N Engl J Med*. 2012; 366: 1705-1715.
- Athappan G, Patvardhan E, Tuzcu EM, et al. Incidence, predictors, and outcomes of aortic regurgitation after transcatheter aortic valve replacement: meta-analysis and systematic review of literature. *J Am Coll Cardiol*. 2013; 61: 1585-1595.
- Linke A, Wenaweser P, Gerckens U, et al; For the ADVANCE study Investigators. Treatment of aortic stenosis with a self-expanding transcatheter valve: the International Multi-centre ADVANCE Study. *Eur Heart J*. 2014; 35: 2672-2684.
- Abdel-Wahab M, Mehilli J, Frerker C, et al. Comparison of balloon-expandable vs self-expandable valves in patients undergoing transcatheter aortic valve replacement: the CHOICE randomized clinical trial. *JAMA*. 2014; 311: 1503-1514.
- Amat-Santos IJ, Dahou A, Webb J, et al. Comparison of hemodynamic performance of the balloon-expandable SAPIEN 3 versus SAPIEN XT transcatheter valve. *Am J Cardiol*. 2014; 114: 1075-1082.
- van der Boon RM, Nuis RJ, Van Mieghem NM, et al. New conduction abnormalities after TAVI—frequency and causes. *Nat Rev Cardiol*. 2012; 9: 454-463.

29. Matthews IG, Fazal IA, Bates MG, Turley AJ. In patients undergoing aortic valve replacement, what factors predict the requirement for permanent pacemaker implantation? *Interact Cardiovasc Thorac Surg.* 2011; 12: 475-479.
30. Bagur R, Rodés-Cabau J, Gurvitch R, et al. Need for permanent pacemaker as a complication of transcatheter aortic valve implantation and surgical aortic valve replacement in elderly patients with severe aortic stenosis and similar baseline electrocardiographic findings. *JACC Cardiovasc Interv.* 2012; 5: 540-551.
31. Blackman DJ, Baxter PD, Gale CP, et al; National Institute for Cardiovascular Outcomes Research (NICOR). Do outcomes from transcatheter aortic valve implantation vary according to access route and valve type? The UK TAVI Registry. *J Interv Cardiol.* 2014; 27: 86-95.
32. Gurvitch R, Webb JG, Yuan R, et al. Aortic annulus diameter determination by multidetector computed tomography: reproducibility, applicability, and implications for transcatheter aortic valve implantation. *JACC Cardiovasc Interv.* 2011; 4: 1235-1245.
33. Barbanti M, Yang TH, Rodés Cabau J, et al. Anatomical and procedural features associated with aortic root rupture during balloon-expandable transcatheter aortic valve replacement. *Circulation.* 2013; 128: 244-253.
34. Barbanti M, Leipsic J, Binder R, et al. Underexpansion and ad hoc post-dilation in selected patients undergoing balloon-expandable transcatheter aortic valve replacement. *J Am Coll Cardiol.* 2014; 63: 976-981.