

## Original Research

# Venous Drug-Eluting vs. Bare-Metal Stenting: An Experimental Animal Study Using Frequency-Domain Optical Coherence Tomography

PANAGIOTIS M. KITROU<sup>1</sup>, STAVROS SPILIOPOULOS<sup>1</sup>, KONSTANTINOS KATSANOS<sup>1</sup>, STAVROS TSANTIS<sup>2</sup>, ATHANASIOS DIAMANTOPOULOS<sup>1</sup>, PANAGIOTIS KALLIDONIS<sup>3</sup>, MARIA KYRIAKOPOULOU<sup>1</sup>, GEORGE C. KAGADIS<sup>2</sup>, DIMITRIOS KARNABATIDIS<sup>1</sup>, DIMITRIOS SIABLIS<sup>1</sup>

<sup>1</sup>Department of Diagnostic and Interventional Radiology, Patras University Hospital, <sup>2</sup>Department of Medical Physics, School of Medicine, University of Patras, <sup>3</sup>Department of Urology, Patras University Hospital, Patras, Greece

Key words: **Vein, drug-eluting stent, rabbit, optical coherence tomography.**

Manuscript received: October 9, 2012;  
Accepted: May 28, 2013.

Address:  
Panagiotis Kitrou

Department of Diagnostic and Interventional Radiology  
Patras University Hospital, 265 00 Patras, Greece  
[panoskitrou@gmail.com](mailto:panoskitrou@gmail.com)

**Introduction:** This protocol was designed to evaluate the safety and feasibility of implanting drug-eluting stents (DES), as well as to compare their long-term results versus bare-metal stents (BMS), in a rabbit venous model, using frequency-domain optical coherence tomography (FD-OCT).

**Methods:** Thirteen New Zealand white rabbits underwent implantation of a zotarolimus-eluting stent in the iliac vein (DES Group) and a BMS in the contralateral iliac vein (BMS Group). The study's primary endpoints included technical success and the comparison of in-stent neointimal hyperplasia in the two study groups, using *ex vivo* FD-OCT, at 3 months.

**Results:** Thirteen DES and 13 BMS were successfully implanted. The technical success rate was 100% (26/26 stents). Three animals (3/13, 23.0%) died within the first 45 days. The remaining 10/13 animals (77%) were euthanized on the 90th day following stent implantation. The 20 stents were successfully removed. Successful *ex vivo* FD-OCT was performed in all stent-implanted iliac vein segments, 10 in the DES Group and 10 in the BMS Group. There was no statistically significant difference in the mean neointimal thickness between the two groups ( $3.02 \pm 1.19 \text{ mm}^2$  in DES Group vs.  $2.76 \pm 1.17 \text{ mm}^2$  in BMS Group;  $p=0.0501$ ).

**Conclusions:** In this experimental protocol, DES implantation in the venous system was safe and feasible. Hyperplasia thickness was similar in both groups after 3 months' follow up.

**P**ercutaneous transluminal balloon angioplasty (PTA) has come to be considered an established method for the treatment of benign venous stenotic disease. However, the reported restenosis rates following PTA in the venous system remain high.<sup>1</sup> Bare metal stents (BMS) have been utilized for the management of benign venous stenosis, but their effectiveness remains controversial and their use is mainly reserved as a bailout method following suboptimal angioplasty.<sup>1,2</sup> Drug-eluting stents (DES)

have been widely used for the treatment of coronary arteries, while recent large-scale randomized multi-center trials provided level A evidence regarding their superiority over PTA and BMS in the management of below-the-knee arterial occlusive disease.<sup>3,4</sup> However, data regarding the safety and effectiveness of DES application in the venous system are missing.

The purpose of this experimental protocol was to investigate the safety and feasibility of DES application in the venous

system, and to compare the long-term outcomes of DES vs. BMS placement, in a rabbit venous model using frequency-domain optical coherence tomography (FD-OCT).

## Methods

This experimental protocol conformed to the EU directive and the EU guidelines for the accommodation and care of animals (NIH Publication No. 85-23, revised in 1996) and was approved by the University Ethics Committee and the Provincial Authority. The venous animal model included 13 New Zealand white rabbits (*Oryctolagus cuniculus*, male sex) that underwent the implantation of a balloon-expandable zotarolimus-eluting stent in the iliac vein of one limb (DES Group) and a balloon-expandable BMS in the iliac vein of the contralateral limb (BMS Group). The study's primary endpoints included technical success, defined as the successful deployment of DES into the rabbit's venous system, and the comparison of in-stent restenosis, expressed as in-stent neointimal thickness measured using *ex vivo* FD-OCT, between the two study groups after 3 months' long-term follow up.<sup>5</sup> Secondary endpoints included successful FD-OCT imaging, defined as the successful visualization of at least 3 quadrants of the vessel lumen and vein wall, throughout the whole stented length, following its surgical removal.

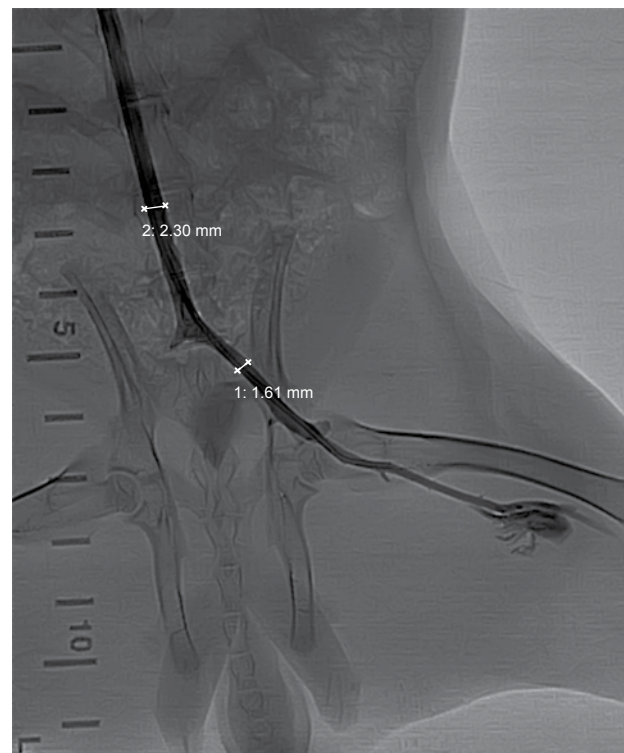
### Zotarolimus-eluting stent

The device used in this protocol was the Endeavor Resolute Zotarolimus-Eluting Coronary Stent System (Medtronic, Inc.), which is composed of four main systems: the delivery system, the stent system (a pre-mounted cobalt alloy-based stent), the polymer system (BioLinx™), and the drug zotarolimus. The device uses a rapid exchange, low profile, balloon catheter, while the stent mesh is covered with a special polymer system, in which the drug is coated, composed of a hydrophilic and a hydrophobic part. The hydrophilic part of the polymer covers the lumen surface, creating biocompatibility with the blood's components, while the outer hydrophobic surface assists in the homogeneous and controlled release of zotarolimus. More than 85% of the drug is released within 60 days and complete drug release occurs in 180 days. Zotarolimus is a semi-synthetic derivative of rapamycin, with a cytostatic action that stops the cell cycle in phase G1. It is a sirolimus analogue with a more li-

pophilic nature. This property favors crossing of cell membranes and delivery to target cells, but also prevents rapid release of the drug into the systemic circulation. The stent used as a control in this experiment was the Azule™ balloon expandable BMS (Orbus Neich, Wanchai, Hong Kong).

### Procedure

All animals were anesthetized with a subcutaneous injection of 5 mg/kg ketamine and 10 mg/kg xylazine solution. Access to the iliac veins was achieved using trans-auricular access with a 4-French arterial sheath and a 4-French catheter, as previously described by Karnabatidis et al.<sup>6</sup> A bolus dose of 1000 UI intravenous heparin was injected at the beginning of the procedure. Digital subtraction angiography (DSA) images were obtained using the Philips Allura Flat-Panel Angiography Unit (Philips, Germany) with an acquisition protocol of 1 image/s. Selective DSA was performed with hand injection of nonionic iodinated contrast (Visipaque 320, GE Healthcare, Pollards Wood, UK) at a rate of 1 mL/s (a total contrast vol-



**Figure 1.** Quantitative vascular angiography. Digital subtraction angiography image demonstrating the semi-automated quantitative vessel analysis system used in this protocol in order to obtain an exact measurement of the vein diameter prior to stent deployment.

ume of 5 mL) through the catheter. The stent's diameter was calculated to exceed the reference vessel diameter by 1 mm, calculated by quantitative vessel analysis performed using semi-automated software (Figure 1). A standard 0.018-inch hydrophilic guidewire (Terumo, Tokyo, Japan) was used to negotiate the iliac vessels, and was subsequently exchanged for a 0.014-inch guidewire (Terumo, Tokyo, Japan) for the delivery and deployment of the stents. All stents were randomly inserted in the right or left iliac veins and were chosen accordingly to reach the same diameter after dilatation at 10 atm. Final check venography was always performed after the insertion of both stents (Figure 2) and a 4-French catheter was left in the right ear of the rabbits as a future access point. A dose of ampicillin C (10 mg/kg) was injected subcutaneously at the end of the procedure. No other antiplatelet therapy was used. On the prescheduled day of euthanasia and *ex vivo* FD-OCT, surgical resection of the stented vessels was performed and the stent was removed, along with at least a 5 mm vein segment at the edge of each stent bilaterally. The specimens were subsequently introduced into a normal saline bath and the 0.014-inch guide-wire with the OCT fiber was positioned across the specimen to perform intravascular FD-OCT image acquisition (Figure 3).

### OCT data analysis method

All OCT frames containing stent struts from both groups were used for analysis. A special algorithm integrating textural and edge information for vessel lumen border extraction and strut detection in intravascular OCT images was used, as previously reported.<sup>7</sup> Firstly, lumen contour was extracted using the Markov random field model (MRF) and continuous wavelet transform (CWT) analysis. Subsequently, a classification scheme based on probabilistic neural networks (PNN), employing the scale-space signatures representation, was used to accurately detect struts. From the lumen contour and the strut positions derived for each OCT frame, two parameters were calculated: lumen area ( $A_L$ : corresponding to the cross-sectional lumen area at the time of the OCT acquisition after development of neointimal thickness [NIT], in  $\text{mm}^2$ ) and stent area ( $A_S$ : corresponding to the cross-sectional vessel area immediately after stent placement, also in  $\text{mm}^2$ ). The total NIT area ( $A_{\text{NIT}}$ ) was then calculated as follows (Figure 4):

$$A_{\text{NIT}} = A_S - A_L$$

Finally, for each case the mean total NIT area values within the total length of stents were extracted towards evaluation of the experimental study.

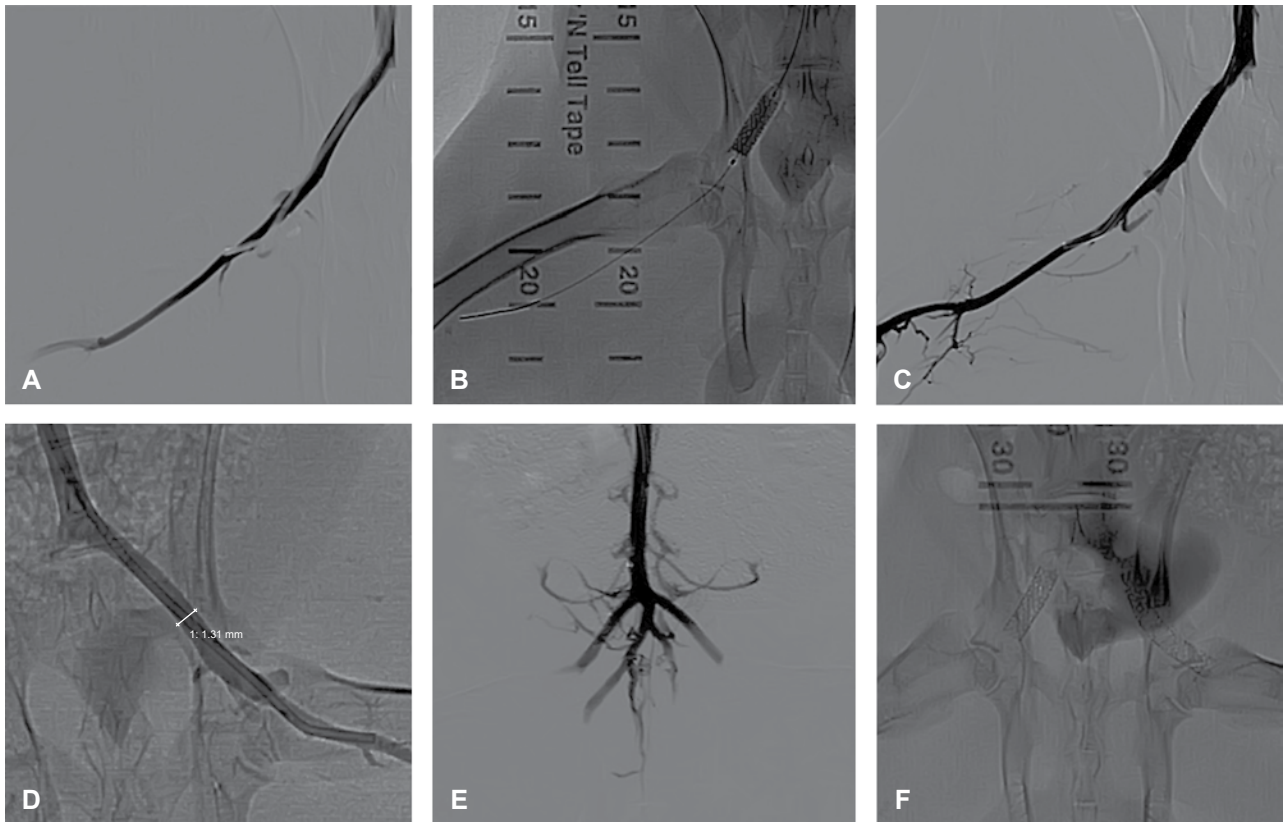
### Statistical analysis

Statistical analysis was implemented using the Graphpad Prism statistical software package (Graphpad Prism version 5.0, San Diego, USA). Discrete and categorical variables were expressed as numbers and percentages, while continuous variables were expressed as mean  $\pm$  standard deviation (SD). The unpaired Student t-test verified the significance of differences between variables that passed the normality test. The Mann-Whitney test was used for qualitative variables and for continuous variables that did not pass the normality test. Statistical significance was set at a p-value  $<0.05$ .

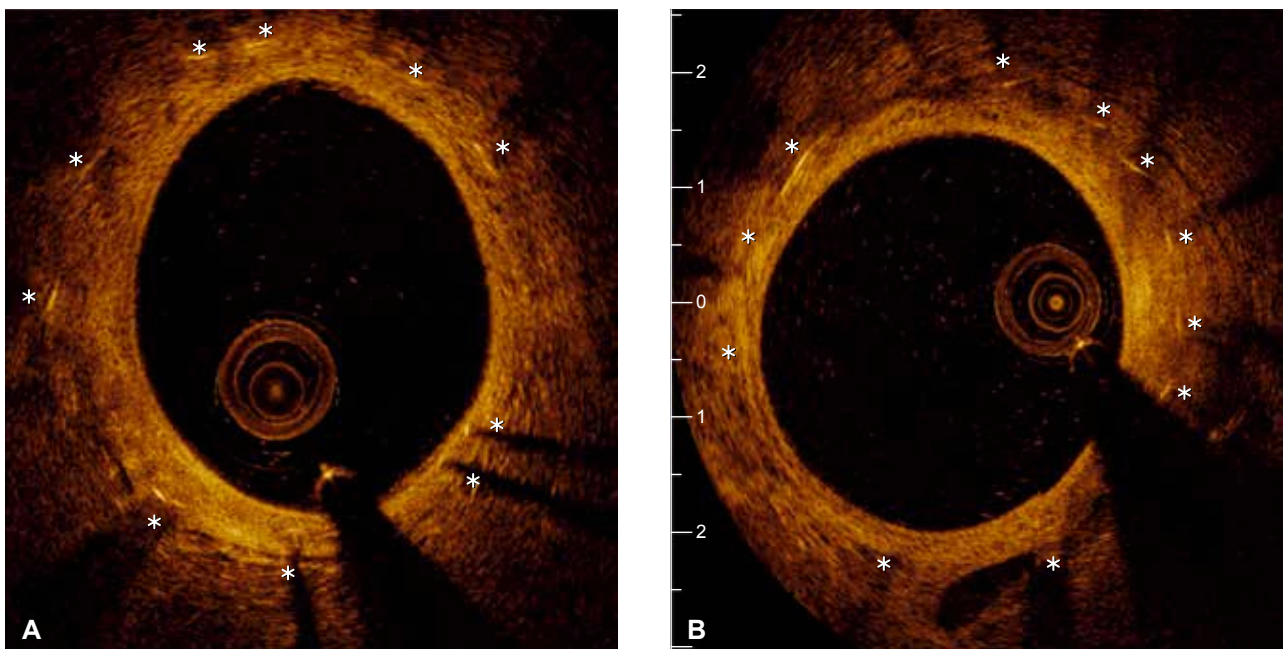
### Results

A total of 13 zotarolimus-eluting stents (DES Group) and 13 bare-metal stents (BMS Group) were successfully implanted in 26 iliac veins of 13 New Zealand white rabbits (mean age  $3 \pm 0.4$  months, mean weight  $3.1 \pm 0.3$  kg). The technical success rate was 100% (26/26 stents). The diameter (D) of the deployed stents ranged between 3 and 4 mm and the lengths (L) between 9 and 28 mm. There was no significant difference in their mean values between the two study groups: DES-group: D=3.5 mm, L=16.3 mm; BMS-group: D=3.7 mm, L=13.5 mm.

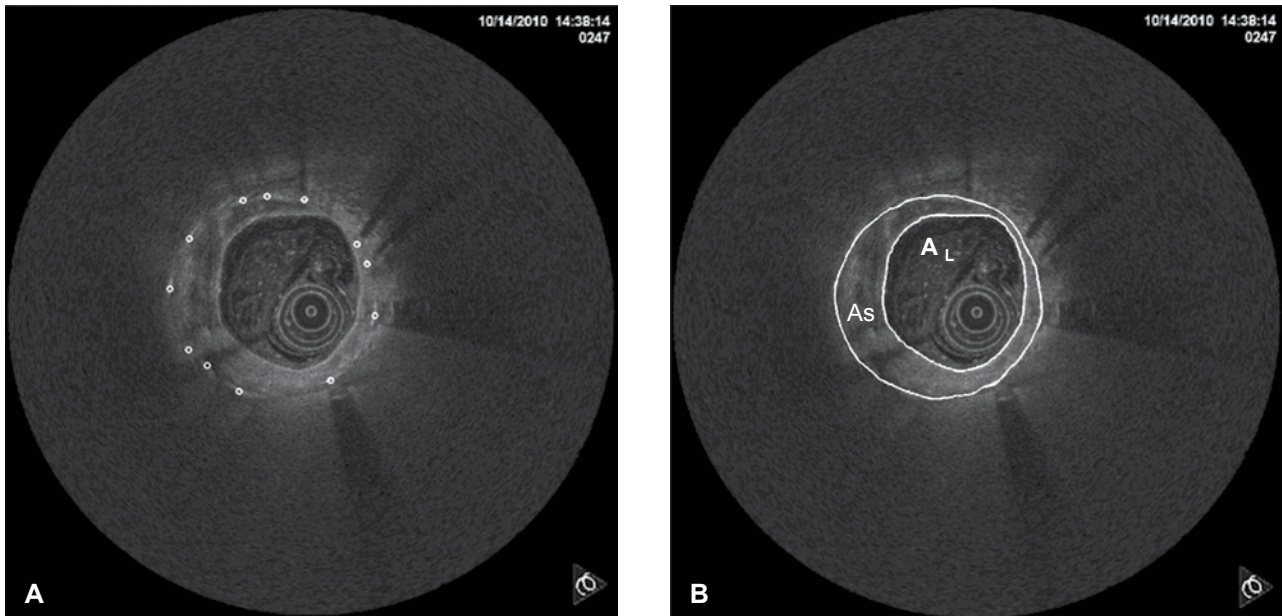
Three animals (3/13, 23.0%) died from infection within the first 45 days of the experiment. The remaining 10/13 animals (77%) were euthanized on the 90th day following stent implantation. In all euthanized animals (n=10, 100%), laparotomy was performed and all 20 implanted stents, including at least a 0.5 cm margin of native vein bilaterally, were successfully removed. Successful *ex vivo* FD-OCT was performed in all the collected 20 stent-implanted iliac vein segments (100%), 10 in the DES Group and 10 in the BMS Group, immediately after successful surgical removal (Figure 4). The mean neointimal thickness was similar in both groups ( $3.02 \pm 1.19 \text{ mm}^2$  in the DES Group vs.  $2.76 \pm 1.17 \text{ mm}^2$  in the BMS Group;  $p=0.05$ ) (Figure 5). Procedural characteristics are summarized in Table 1.



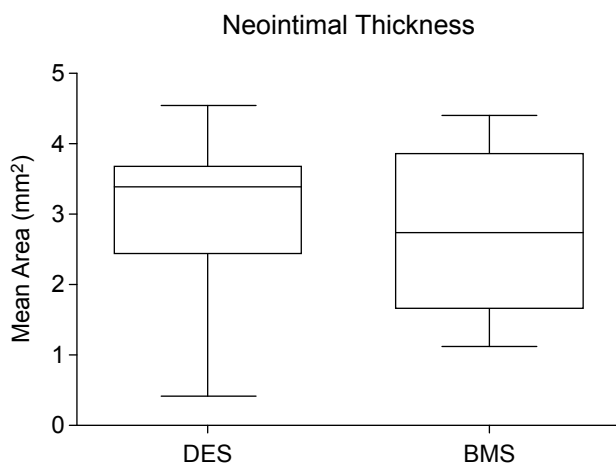
**Figure 2.** Procedure. Digital subtraction angiography images demonstrating the main procedural steps. (A) Selective catheterization of the right iliac vein. (B) Drug-eluting stent (DES) positioning. (C) Selective venogram following DES deployment. (D) Selective catheterization and quantitative vascular angiography of the contralateral iliac vein. (E) Final venogram after deployment of both DES and bare-metal stent. (F) X-ray image depicting the correct deployment of the stents in the common iliac veins.



**Figure 3.** *Ex vivo* optical coherence tomography (OCT) imaging. OCT images demonstrating minimal in-stent neointimal hyperplasia within the stent struts (asterisks) at 3-month follow up following implantation of drug-eluting (A) and bare-metal (B) stents.



**Figure 4.** Neointimal thickness (NIT) analysis. (A) White circles indicate the strut positions detected by the proposed algorithm. (B) The outer boundary represents the b-spline interpolation of all strut positions toward neointimal hyperplasia estimation and the inner boundary represents the vessel border. The total NIT area (ANIT) was calculated according to the formula,  $A_{NIT} = A_S - A_L$ , where  $A_S$  is the cross-sectional vessel area immediately after stent placement and  $A_L$  is the cross-sectional lumen area at the time of the optical coherence tomography acquisition after the development of NIT.



**Figure 5.** Box-plot demonstrating in-stent neointimal thickness in the drug-eluting stent (DES) and bare-metal stent (BMS) groups.

**Discussion**

Restenosis following balloon angioplasty has always been the major disadvantage of the percutaneous endovascular management of venous benign stenotic disease.<sup>1</sup> Although studies investigating the use of new-generation self-expandable BMS have recently reported a satisfactory 71% 3-year primary patency

**Table 1.** Summary of procedural characteristics.

	BMS	DES
Number of common iliac veins treated	13	13
Number of stents deployed	13	13
Technical success (%)	100	100
Number of deaths*	3/13	3/13
Mean pre-stenting vessel diameter (mm)	2.6	2.6
Mean stent diameter (mm)	3.7	3.5
Mean stent length (mm)	13.5	16.3
OCT performed	10/13	10/13
Mean neointimal thickness (mm <sup>2</sup> )	2.76 ± 1.17	3.02 ± 1.19

\*Prior to 90 days, due to infection. BMS – bare-metal stent; DES – drug-eluting stent; OCT – optical coherence tomography

rate, bare stents are still not considered as the established treatment method for benign venous disease and are mainly used in specific pathologies, such as May–Turner syndrome, and as a bailout option.<sup>1,8-10</sup>

Various innovative endovascular devices, such as paclitaxel-coated balloons, have been used to improve primary patency rates by reducing long-term restenosis rates following endovascular venous procedures.<sup>11</sup> Considering that DES demonstrate superior clinical and angiographic results compared with BMS in coronary and below-the-knee arteries,<sup>3</sup> the

authors designed the specific experimental protocol in order to investigate the long-term safety, feasibility and effectiveness of DES application in veins, as this has not been previously reported and experimental studies regarding the application of DES in animal venous model are lacking. The safety and effectiveness of DES noted in the arterial system cannot be simply extended to the venous system, as veins differ from arteries in terms of vascular wall anatomy, flow dynamics, and other significant physical characteristics. Only within the last few years have data emerged on the venous wall response to restenosis, the cells involved, and their anatomical origin, while vascular smooth muscle cells and myofibroblasts have been shown to play a key role in this phenomenon. Venous wall changes in dialysis circuits due to uremia, oxidative stress and inflammation caused by end-stage renal disease plus venous “arterialization” in terms of flow dynamics, has been the center of interest for everyone involved in the treatment of the huge dialysis population.<sup>12</sup> However, all these studies were orientated towards hemodialysis circuits and anastomotic arteriovenous sites, while even the basic mechanisms of native vein restenosis remain unknown. We conducted this experimental protocol using a normal animal vein, as the primary endpoints of this study were to investigate the safety and feasibility of drug-eluting stenting in the venous system, as well as the hyperplastic reaction of the normal vein wall to the trauma induced by the metallic scaffolding following DES implantation, expressed as restenosis, compared to standard BMS. The investigation of restenosis following plain balloon angioplasty or stenting in normal animal arteries (i.e. non-atherosclerotic) has been previously reported and is a well-accepted model for the comparison of various endovascular devices.<sup>13,14</sup>

Our results demonstrated that DES use in the venous system of the normal rabbit vein animal model is feasible and safe, as all DES were successfully deployed and nearly 70% of the animals tolerated the implanted material without any side effects, minor or major complications, during long-term follow up.

The comparison of in-stent lumen loss between DES and BMS was performed using *ex vivo* FD-OCT. To our knowledge, this is the first study using *ex vivo* OCT in stented vein segments. Novel OCT technology has introduced high-resolution intravascular imaging into everyday clinical practice, and this invasive imaging modality has been applied in both the coronary and the peripheral arterial bed.<sup>15</sup> Various studies have verified the accuracy of the method, while

the histopathological correlation of OCT findings has been widely reported.<sup>16,17</sup> Moreover, a high correlation between OCT and histology for the evaluation of neointimal area, luminal area, and neointimal thickness has been reported.<sup>18</sup> The choice to perform *ex vivo* and not *in vivo* OCT imaging was based on the desire to eliminate blood flow, one of the limitations of OCT, with a view to improving the image quality.<sup>15</sup> In addition, OCT imaging in a surgically extracted small vein segment was easier to perform. No significant difference in in-stent restenosis was found between the two groups after 3 months’ follow up, a period considered long-term in experimental animal models.<sup>5</sup> This discrepancy between the outcomes reported from the experimental and clinical comparisons of DES versus BMS in arteries<sup>19,20</sup> could be attributed to the numerous differences between the venous and arterial circulatory system.

### Limitations

The small number of subjects (n=10), along with the fact that both DES and BMS were implanted in normal, healthy veins, represent the limitations of the present experimental protocol. However, as this was a first attempt to examine the venous response to drug-eluting stenting, these limitations underline the importance of experimenting on a larger scale. Moreover, no antiplatelet agent was administered to the animals before, during or after the procedure, as it is not considered mandatory by current guidelines regarding experimental studies.<sup>21</sup> Finally, although both stents used in this protocol utilize new-generation thin strut technology platforms, which demonstrate better results when compared to stainless steel, and they both use cobalt and chromium in their alloy (Azule: cobalt, chromium; Resolute: cobalt, nickel, chromium, and molybdenum), there are no data in the literature as to whether one is superior to the other. As a result, there are no data regarding the influence of each metallic stent mesh on our results. Nevertheless, as both groups demonstrated similar restenosis, one could speculate that both alloys perform similarly.

### Conclusions

In this particular experimental controlled protocol using a normal rabbit vein model, DES application in the venous system was proved to be feasible and safe. However, long-term follow up did not demonstrate

any significant difference in neointimal thickness between the DES and BMS groups.

## References

- Mansour M, Kamper L, Altenburg A, Haage P. Radiological central vein treatment in vascular access. *J Vasc Access*. 2008; 9: 85-101.
- Ozyer U, Harman A, Yildirim E, Aytakin C, Karakayali F, Boyvat F. Long-term results of angioplasty and stent placement for treatment of central venous obstruction in 126 hemodialysis patients: a 10-year single-center experience. *AJR Am J Roentgenol*. 2009; 193: 1672-1679.
- Katsanos K, Spiliopoulos S, Krokidis M, Karnabatidis D, Siablis D. Does below-the-knee placement of drug-eluting stents improve clinical outcomes? *J Cardiovasc Surg (Torino)*. 2012; 53: 195-203.
- Karnabatidis D, Spiliopoulos S, Katsanos K, Siablis D. Below-the-knee drug-eluting stents and drug-coated balloons. *Expert Rev Med Devices*. 2012; 9: 85-94.
- Schwartz RS, Edelman ER, Carter A, et al. Drug-eluting stents in preclinical studies: recommended evaluation from a consensus group. *Circulation*. 2002; 106: 1867-1873.
- Karnabatidis D, Katsanos K, Diamantopoulos A, Kagadis GC, Siablis D. Transarterial or venous access for cardiovascular experimental protocols in animals. *J Vasc Interv Radiol*. 2006; 17(11 Pt 1): 1803-1811.
- Tsantis S, Kagadis GC, Katsanos K, Karnabatidis D, Bourantas G, Nikiforidis GC. Automatic vessel lumen segmentation and stent strut detection in intravascular optical coherence tomography. *Med Phys*. 2012; 39: 503-513.
- Kurklinsky AK, Bjarnason H, Friese JL, et al. Outcomes of venoplasty with stent placement for chronic thrombosis of the iliac and femoral veins: single-center experience. *J Vasc Interv Radiol*. 2012; 23: 1009-1015.
- Jeon UB, Chung JW, Jae HJ, et al. May-Thurner syndrome complicated by acute iliofemoral vein thrombosis: helical CT venography for evaluation of long-term stent patency and changes in the iliac vein. *AJR Am J Roentgenol*. 2010; 195: 751-757.
- Bornak A, Wicky S, Ris HB, Probst H, Milesi I, Corpataux JM. Endovascular treatment of stenoses in the superior vena cava syndrome caused by non-tumoral lesions. *Eur Radiol*. 2003; 13: 950-956.
- Katsanos K, Karnabatidis D, Kitrou P, Spiliopoulos S, Christeas N, Siablis D. Paclitaxel-coated balloon angioplasty vs. plain balloon dilation for the treatment of failing dialysis access: 6-month interim results from a prospective randomized controlled trial. *J Endovasc Ther*. 2012; 19: 263-272.
- Diskin CJ. Novel insights into the pathobiology of the vascular access - do they translate into improved care? *Blood Purif*. 2010; 29: 216-229.
- Spiliopoulos S, Diamantopoulos A, Katsanos K, Ravazoula P, Karnabatidis D, Siablis D. PolarCath cryoplasty enhances smooth muscle cell apoptosis in a rabbit iliac artery model: an experimental in vivo controlled study. *Cryobiology*. 2011; 63: 267-272.
- Steigerwald K, Ballke S, Quee SC, et al. Vascular healing in drug-eluting stents: differential drug-associated response of limus-eluting stents in a preclinical model of stent implantation. *EuroIntervention*. 2012; 8: 752-759.
- Karnabatidis D, Katsanos K, Paraskevopoulos I, Diamantopoulos A, Spiliopoulos S, Siablis D. Frequency-domain intravascular optical coherence tomography of the femoropopliteal artery. *Cardiovasc Intervent Radiol*. 2011; 34: 1172-1181.
- Kim JS, Wallace-Bradley D, Alviar CL, et al. Correlation of angiographic late loss with neointimal proliferation in stents evaluated by OCT and histology in porcine coronary arteries. *JACC Cardiovasc Imaging*. 2011; 4: 1002-1010.
- John R, Adie SG, Chaney EJ, Marjanovic M, Tangella KV, Boppart SA. Three-dimensional optical coherence tomography for optical biopsy of lymph nodes and assessment of metastatic disease. *Ann Surg Oncol*. 2013; 20: 3685-3693.
- Murata A, Wallace-Bradley D, Tellez A, et al. Accuracy of optical coherence tomography in the evaluation of neointimal coverage after stent implantation. *JACC Cardiovasc Imaging*. 2010; 3: 76-84.
- Yeh RW, Normand SL, Wolf RE, et al. Predicting the restenosis benefit of drug-eluting versus bare metal stents in percutaneous coronary intervention. *Circulation*. 2011; 124: 1557-1564.
- Jia H, Liu H, Kong J, et al. A novel polymer-free paclitaxel-eluting stent with a nanoporous surface for rapid endothelialization and inhibition of intimal hyperplasia: Comparison with a polymer-based sirolimus-eluting stent and bare metal stent in a porcine model. *J Biomed Mater Res A*. 2011; 98: 629-637.
- Schwartz RS, Edelman ER, Carter A, et al. Drug-eluting stents in preclinical studies: recommended evaluation from a consensus group. *Circulation*. 2002; 106: 1867-1873.